Digestive and Liver Disease 52 (2020) 245–252

Contents lists available at ScienceDirect

Digestive and Liver Disease

journal homepage: www.elsevier.com/locate/dld

Review Article

Esophageal perforation in eosinophilic esophagitis: A systematic review on clinical presentation, management and outcomes

Laura Arias-González[a,b,c], Esther Rey-Iborra[a], Miriam Ruiz-Ponce[a,c], Emilio J. Laserna-Mendieta[a,c], Ángel Arias[b,d], Alfredo J. Lucendo[a,b,c,*]

[a] Department of Gastroenterology, Hospital General de Tomelloso, Tomelloso, Spain
[b] Centro de Investigacion Biomedica en Red Enfermedades Hepáticas y Digestivas (CIBEREHD), Madrid, Spain
[c] Instituto de Investigación Sanitaria Princesa, Madrid, Spain
[d] Research Unit, Hospital General Mancha Centro, Alcázar de San Juan, Ciudad Real, Spain

ARTICLE INFO

Article history:
Received 27 August 2019
Accepted 29 October 2019
Available online 10 December 2019

Keywords:
Boerhaave syndrome
Eosinophilic esophagitis
Esophageal perforation
Esophageal rupture

ABSTRACT

There is evidence of an increased fragility in the inflamed esophagus of patients with eosinophilic esophagitis (EoE). We performed a systematic review on presentation, management and outcomes of and surgical interventions for esophageal perforation in these patients, by searching in the MEDLINE, Embase and Scopus databases.

Of the 599 references identified, 41 full-papers and 9 abstract met the inclusion criteria. Overall, 76 esophageal perforation episodes in 70 individual patients aged between 9 and 65 years were reported. 51 patients had not been diagnosed with EoE at the time of perforation; 14 patients had an untreated disease and the remaining were non responsive to therapy. Acute or progressive pain after long-lasting dysphagia and food impaction was the most common symptom leading to diagnosis in 42 patients who presented with Boerhaave syndrome. Pushing impacted food into the stomach led to perforation in 5 cases. Eight episodes appeared after dilation. CT scans demonstrated perforation in 82.4% of patients.

Conservative management (including esophageal stenting) was used in 67.1% patients. The 25 remaining patients underwent surgery. Recovery was uneventful in the vast majority of patients. No death was reported.

Active inflammation due to undiagnosed or untreated EoE was present in most cases of esophageal perforation. Conservative treatment of perforation should always be considered in EoE.

1. Introduction

Eosinophilic esophagitis (EoE) is a chronic inflammatory disorder of the esophagus. The growth in incidence reporting of EoE [1] has increased to the point that it currently represents the most common cause of dysphagia and food impaction in children and young adults [2]. EoE is considered a particular form of food allergy, in which proton pump inhibitor (PPI) therapy, topical steroids and elimination diets are effective in inducing and maintaining disease remission [3–5]. Food impaction has been described as the most frequent clinical manifestation that leads to the diagnosis of EoE in adult patients [6,7]. Although it is often self-limited, it sometimes requires the extraction of the impacted food bolus by flexible or rigid esophageal endoscopy [8,9], or advancing the impacted bolus into the stomach [10]. A high rate of tears and lacerations of the mucosa has been also reported in EoE patients [11], demonstrating increased fragility of the esophageal mucosa.

EoE is considered a progressive condition where, if untreated, features of esophageal remodeling develop over time, leading to a diffusely narrow caliber esophagus and dominant strictures which may cause persistent dysphagia and require esophageal dilation [12–15]. Esophageal dilation is one of the most effective options in the management of dysphagia of EoE patients with fibrostenotic features [16], despite it has no impact on underlying inflammation. However, several reports have described a higher than expected rate of complications, especially in the early literature [16–18], thus highlighting the association of EoE with a marked fragility of the organ. In fact, mucosal tears produced spontaneously while trying to dislodge impacted food or following endoscopic procedures are common in active EoE and may be complicated by esophageal perforation, which sometimes constitutes the initial manifesta-

* Corresponding author at: Department of Gastroenterology, Hospital General de Tomelloso, Vereda de Socuéllamos, s/n, Tomelloso, Ciudad Real, 13700, Spain.
E-mail address: ajlucendo@hotmail.com (A.J. Lucendo).

https://doi.org/10.1016/j.dld.2019.10.019
1590-8658/

tion of EoE [19–21]. The most appropriate management of such esophageal perforation is not well established, and data on the outcomes from surgical or conservative options are currently lacking.

The aim of this research was to systematically assess the clinical presentation, management and outcomes of the different interventions for esophageal perforation in patients with EoE, and to determine contributing factors around this complication.

2. Material and methods

We used PRISMA methodology for conducting this systematic review [22], which was registered in PROSPERO, the International Prospective Register of Systematic Reviews (CRD42019125048). There was no funding received for this review.

2.1. Selection criteria

A predetermined protocol was used in accordance with the quality standards for reporting meta-analyses of observational studies in epidemiology [23]. To be included in this review, studies needed to involve adult or pediatric patients with EoE who suffered from esophageal perforation, both spontaneously or after endoscopic interventions. Description of clinical presentation and results of diagnostic tests had to be reported, as well as the intervention performed and its clinical outcomes defined. All kinds of designs for clinical studies - retrospective observational studies, case series, and case reports - were eligible for inclusion.

2.2. Search strategy

A systematic literature search was performed independently by two researchers (AJL and AA) in three major bibliographical databases (PubMed, EMBASE, and Scopus) for the period up to April 2019. The search was not restricted to language of publication. Literature search strategies in these databases used a combination of subject headings and index terms, as well as key words relating to EoE and an esophageal perforation. The following search strategy was used to consult the thesauri for MEDLINE (MESH) and EMBASE (EMTREE): ("eosinophilic esophagitis" OR "eosinophilic oesophagitis") AND ("esophageal perforation" [MeSH Terms]) OR "perforation" OR "dissection" OR "rupture" OR "Boerhaave*"). As for the SCOPUS database, only free text searches with truncations were carried out. Reference lists from retrieved articles and abstracts of conference proceedings (taken from abstract books from the annual Digestive Diseases Week, American College of Gastroenterology Meetings and the United European Gastroenterology Week for the period between 2014 and 2018) were also examined to identify additional, relevant studies. All references were screened for eligibility independently by four reviewers (LA-G, MR-P, ER-I & AJL). If any of the reviewers felt that a title or abstract met the study eligibility criteria, the full-text of the study was retrieved. The authors resolved any discrepancies by discussion.

2.3. Inclusion criteria

EoE was defined by any combination of symptoms pointing to esophageal dysfunction and a dense eosinophilic infiltration ($\geq$15 eosinophils per high power field) in esophageal biopsies [2]; esophageal perforation was considered as any rupture of the esophageal wall associated with mediastinal or thorax fluid or air findings in image tests. Any treatment received by the patient to manage a perforation in which surgery was not involved was considered a conservative approach.

2.4. Exclusion criteria

Systematic reviews, guidelines, review articles, book chapters, letters to the editor or editorials with no original data were excluded. Studies providing duplicate information to include subsets of data already published and those providing no information on the management of perforation were also excluded, as were studies not carried out on humans.

2.5. Data extraction

Four reviewers (AJL, LA-G, MR-P and ER-I) independently extracted relevant information from each eligible study using a standardized data extraction sheet and then proceeded to cross-check the results. The data extracted included the last name of first authors, publication year, journal name, type of document, country or origin, age and gender of patients reported, length of EoE at complication (if available), symptoms leading to diagnose a perforation, cause of perforation, type of perforation, technique to diagnose perforation, findings from examinations, need of surgery to treat perforation, additional treatment measures, and patient outcome. Disagreements between reviewers regarding data extraction were resolved through discussion.

2.6. Risk of bias assessment

Retrieved documents were evaluated for risk of bias if the article described patients' demographical data, and the diagnostic criteria used for EoE, reported on the presentation of the complication, and the diagnostic tests or assessment methods, had clearly presented results, and if the intervention or treatment procedure(s) were clearly described. Information on the post-intervention clinical condition also needed to be reported. Risk of bias assessment was checked against The Joanna Briggs Institute Critical Appraisal Checklist for Case Reports [24]. A study was considered to be at low risk for bias if each of the bias items could be categorized as low risk. Studies were judged to have a high risk of bias however if any one of the items was deemed high risk. Four investigators (AJL, LA-G, MR-P and ER-I) independently gave each eligible study an overall rating of high, low or unclear risk of bias; disagreements were resolved by consensus.

2.7. Analysis data and reporting

A descriptive summary with data tables was produced to summarize the findings of the review, along with a flow chart of the review process, and included as a figure. Quantitative pooling of data was not meaningful in the context of this review so a narrative synthesis of the data was undertaken.

3. Results

3.1. Literature search

The search strategy yielded 599 references after removing duplicates; 543 were excluded from the search mainly due to (a) being review articles or book chapters, (b) EoE with no perforation reported, (c) perforations not related with EoE or (d) details on the management of the perforation not being provided. Screening of references of chosen articles provided 3 additional documents. In all, we identified 50 studies that reported on the management and outcomes of esophageal perforation in patients with EoE. Fig. 1 summarizes the results of the search strategy.

Most of the studies were conducted in United States (US) [20,21,25–43] and European countries, including Spain [19,44–50],

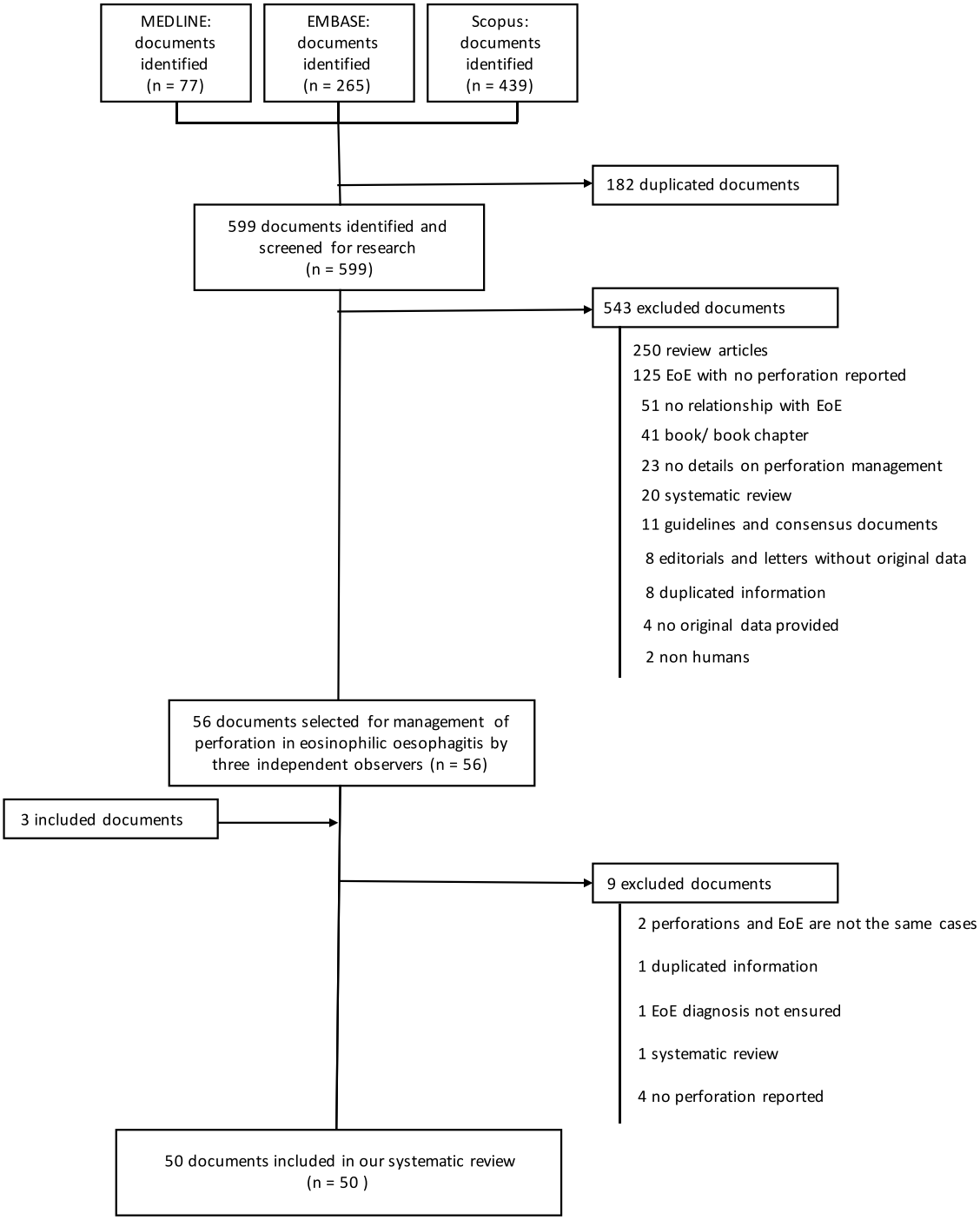

Fig. 1. Flow chart for the process of identifying studies included in and excluded from the systematic review.

Switzerland [8,51,52], Portugal [53–55], Germany [56–58], The Netherlands [59,60], Italy [61–63], United Kingdom [64–66], Sweden [67], Iceland [68], and France [69]. One additional study came from Australia [70]. The first study was published as early as 1996 [65], and the second appeared in 2003 [34]. Thereafter, the number of cases reported increased almost continuously up to 2019.

Overall, studies retrieved included 41 full-paper reports and 9 abstracts, which described 70 patients who suffered from 76 esophageal perforations overall. Most the studies were single case reports, but some of them described case series of 2–10 individual patients [8,19,21,30–32,35,43,68]. Supplementary Table 1 provides a summary of the studies reviewed and key patient data and progression.

Fifty-one patients were male, 14 were female (the ratio of M:F being 3.3:1) and for the remaining 5 the gender was not provided. At the moment of suffering a perforation, thirteen patients (18.6%) were children and adolescents (with ages ranging from 10 to 17 years); 35 patients (46%) were in the age range of 18–35 years; and 20 patients (26.3%) aged between 36 and 53 years old. The last 3 patients (3.9%) were over 54 years of age. No data was provided for the 5 remaining patients. Demographic and clinical characteristics of the patients included in this systematic review are shown in Table 1.

Table 1
Demographic and clinical characteristics of patients with eosinophilic esophagitis suffering from esophageal perforation.

Demographic characteristics	Patients (%)
N	70
Age at perforation[a] (years) [Mean (SD; range)]	30.9 (11.9; 11–65)
Sex [male (%)/female (%)/unspecified (%)]	51 (72.9)/14 (20)/5 (7.1)
Age group at perforation[a] (years) [N (%)]	
<18	13 (17.1)
18–35	35 (46.1)
36–53	20 (26.3)
≥54	3 (3.9)
Unspecified	5 (6.6)
Previously diagnosed with EoE	
No (%)	51 (67.1)
Yes, but untreated (%)	14 (18.4)
Yes, but treatment ineffective (%)	7 (9.2)
Yes, but not adherent (%)	1 (1.3)
Unspecified (%)	3 (3.9)

[a] Patients suffering two episodes of esophageal perforation twice are counted twice.

3.2. Clinical pictures of esophageal perforation in patients with EoE

3.2.1. Clinical presentation of esophageal perforations

In 51 out of the 76 episodes of esophageal perforation (67.1%), no treatment was being offered, since the patients had not been diagnosed with EoE at the time of presenting the complication. Fourteen patients (18.4%) who presented esophageal perforation had already been diagnosed for EoE, but were not receiving therapy at the point of presenting the perforation [21,67,31,53,33,35,50,43,42]. Seven additionalpatients were receiving topic steroids (mainly metered fluticasone) [8,28,32,59] or PPIs [63] when the perforation appeared, but were histologically non-responsive and one patient was treated exclusively with endoscopic dilation [50]. Details on EoE therapy were not provided for 3 patients reported in 2 studies [34,68]. Six patients suffered from esophageal perforation twice, and the underlying cause of perforation was not investigated after the first episode.

The most common symptom that led patients to seek medical attention were dysphagia and food impaction [8,19,29,31–34,43,45,46,57,59,60,62,66,68,70], which was occasionally followed by acute or progressive chest or epigastric pain [8,20,25,29,30,35,37,39,42,43,47,48,50,53,61,63,65,69], fever [40,52,53,55,69] or dyspnea [21,27,40,65]. Some patients also presented hematemesis [8,37,38,41,43,54,61,63]. It was not unusual for patients to seek attention due to onset of severe chest pain after a persistent esophageal impaction for several hours or even days [21,43,58,63].

Esophageal perforation occurred after retching or vomiting (resulting in a Boerhaave syndrome) in 41 patients (two of them suffered two perforations at different times) [8,19–21,25–27,29,30,35,37,39–43,47,48,50,53,55,61,62,65,68,69]. In 8 cases perforation appeared as a complication after endoscopic dilation with through-the scope balloons (6 cases) or Savary bougies (2 cases) [32,33,35,43,56]; resolving food impaction by pushing food into the stomach with the aid of the scope led to perforation in 5 cases [31,60,66,67,70]; 3 perforations occurred after biopsy sampling [44,45,49] and 2 after food bolus removal by rigid esophagoscopy [8]. A poorly tolerated endoscopy led to Mallory Weiss syndrome and esophageal perforation in 3 cases [38,49,57]; dislodging of food [43,59] or tablets [54,58] were reported as causing perforation also, as well as difficult esophageal strictures [43,68]. Finally, some miscellaneous cases of perforation were cause by transesophageal echocardiogram [28], HALO ablation of Barrett esophagus [36], chest trauma [52] or the mere passage of the endoscope [34].

Table 2
Findings from exploratory exams carried out in 70 patients with eosinophilic esophagitis who suffered from 76 episodes of esophageal perforation, as described by authors in source documents included in our systematic review. Several finding could be present in the same patient.

Exploratory findings	N (%)
Pneumomediastinum	40 (57.1)
Esophageal mucosa of fragile appearance	24 (34.3)
Subcutaneous emphysema	10 (14.3)
Contrast extravasation/esophageal leak	10 (11.4)
Pleural effusion	7 (10.0)
Fluid or gas abscess or collections	6 (8.6)
False lumen/mucosal flap/double-barrel	6 (8.6)
Mucosal striping/tears	5 (7.1)
Purulent content in esophageal lumen	5 (7.1)
Esophageal ulceration	4 (5.7)
Thickening of esophageal mucosa	4 (5.7)
Narrowed esophagus	3 (4.3)
Pneumoperitoneum	3 (4.3)
Pneumopericardium	3 (4.3)
Mediastinitis	3 (4.3)
Pneumothorax	2 (2.9)
Esophageal wall pneumatosis	2 (2.9)
Phrenic nerve injury	2 (2.9)
Peritonitis	1 (1.4)
Emphysema dissenting the thyroid gland	1 (1.4)

3.2.2. Symptoms leading to suspicion of perforation

In most of the reported cases, the symptoms that led to the suspicion of esophageal perforation were different to those that prompted the patient to seek medical attention, especially in cases where the perforation had been caused by endoscopic intervention. Thus, the onset of severe pain in the neck and chest [8,19,25,30,33,43,45,56,58,63,65,66], the appearance of subcutaneous emphysema [43,46,62,66] or profuse bleeding after endoscopy [28,43,44,58] were major signs to suspect esophageal perforation.

3.2.3. Diagnostic tests

A computed tomography scan of neck, thorax and/or abdomen was reported (92.1%) to be used to demonstrate esophageal perforation in 56 out of the 70 episodes. CT scanning was usually accompanied by other complimentary imaging techniques performed either beforehand or afterwards. The most common of these were: chest x-ray [8,29,31,40,45,64–66], water soluble contrast-esophagogram [26,27,30,35,40,43,47,50,63–65], and endoscopy [19,28,39,40,52,53,55,61,62,65]. In a minority of cases a perforation was diagnosed based exclusively on endoscopy [43,49,59], gastrografin swallow [8,21,37,43,70], chest or abdomen x-ray [19,33,43,60].

The perforation was described as an esophageal rupture by the original authors in 62 episodes (81.6%); in 11 episodes (14.5%), the perforation was described as esophageal dissection and in 3 cases (3.9%) it was described as an esophageal leakage.

Regarding the exploratory findings, pneumomediastinum was the most common, described in 40 patients (57.1% of perforations); an altered esophageal wall was found in 24 patients (34.3% of perforation); and a subcutaneous emphysema was present in 10 patients (14.3% of episodes). Table 2 shows detailed exploratory finding in the complete series of patients included in this review.

3.3. Management of esophageal perforations in EoE

Fifty-one out of the 76 episodes of esophageal perforation (67.1%) were managed conservatively with no need for surgery [8,20,21,26,28–35,38–45,47–51,53–60,63,67–69]; this mainly consisted of *nil per os* with parenteral diet, broad-spectrum antibiotics, proton pump inhibitors and analgesics. Among these patients, 10 underwent esophageal stenting as the primary measure to close the

perforation [20,28,31,51,54,57,59,60,67]. Both full- and partially covered metallic stents were used.

In two patients the primary mucosal tear was endoscopically closed with endoscopic clips [40] or over-the-scope clips [41]. A patient who presented transmural wall dissection of the esophagus with no leak in the mediastinum, underwent resection of the mucosal septum to create a single esophageal lumen [61].

The remaining 25 patients (32.9% of perforations) underwent surgery, which mainly included repair of the perforation through thoracotomy [19,25,27,30,35,37,43,62,64–66] or, less commonly, laparotomy [37] or laparoscopy [19]. An esophagectomy with gastroplasty was performed in 5 cases [30,36,46,62,65]. Only 1 patient required an esophageal stoma and feeding jejunostomy, followed by reconstructive gastrosplasty [70].

In a patient who presented with Boerhaave syndrome, a left thoracotomy and coverage of the perforation with intercostal muscle flap was combined with esophageal stenting [35]; an additional patient required esophageal stenting to closure a persistent leak after surgical repair of the perforation [37]. Details on therapeutic interventions are summarized in Table 3.

Comparison between groups of patients undergoing surgically versus conservative treatment revealed that the only findings that made surgical management more likely than a conservative one were pleural effusion (5 out of 7 patients with this complication were operated on) and contrast extravasation out of the esophageal lumen (5 out of 8 patients presenting it underwent surgery). The date of publication of each report and the use of a strategy for the preferential management of esophageal perforation were not related.

3.4. Clinical outcomes of perforation in patients with EoE

Most of the cases recovered uneventfully, and 21 patients out of the 29 for whom the length of hospital stay was provided, were discharged from hospital within a 1week period (72.4% of perforations). Hospital discharge happened in the second week after perforation in 7 patients and the remaining were discharged later due to the need for a more complex post-operative course which required continuous drainage from the site of rupture – mediastinal lavage and bilateral chest tubes – over a 3-month period [30].

Most of the esophageal stents were removed before the third week from placement and all of them before the eighth week; two patients with partially covered stents presented tissue in-growth and required a stent-in-stent procedure for their removal [31,59].

EoE was diagnosed after the first esophageal perforation in 32 patients out of 48 who had no previous diagnosis (66.7%); five additional patients were diagnosed from EoE after suffering a second episode of perforation [27,31,37,40,49]. A diagnosis of EoE had been provided to the remaining patients before suffering perforation.

3.5. Risk of bias assessment

Of the 50 studies, 22 were considered low risk of bias, and 15 others judged intermediate. Reasons for reducing the quality of reporting in the remaining 13 studies were mainly due to: insufficiently detailed description of diagnostic test results (3 studies), not providing clear descriptions on interventions or treatment procedures (9 studies), not providing detailed information on post-interventional management and outcomes (8 studies). Supplementary Table 2 provides a detailed evaluation of the critical appraisal for each of the studies.

4. Discussion

This is the first research that systematically reviews the occurrence of esophageal perforation in patients with EoE, by undertaking an exhaustive search of the literature and analysis of 76 episodes in 70 patients covering a wide age range. At present this represents the widest collection of esophageal perforations described in the literature, covering a broad period of time, and showing a marked increase with the most cases described in recent years.

Our research supports esophageal perforation, either after food impaction or following an endoscopic procedure, as a well-defined complication of EoE, related to the greater fragility of the esophageal mucosa in these patients [71]. Cytotoxic proteins contained in eosinophil granules have been connected to an increased fragility of esophageal tissues in such patients and can lead to damage by increasing the risk of esophageal disruption [72]. Eosinophils in EoE infiltrate not only the epithelial layers, but also permeate throughout the entire esophageal wall, including the lamina propria and the submucosa [73,74], dissect muscle fibers of muscularis propria [46,75] and reach parasympathetic ganglion cells of the myenteric plexus [46]. These clinical implications determine dysphagia and explain not only strictures and dysmotility, but also the deep esophageal tears and perforations which result from vomiting to dislodge impacted food (Boerhaave syndrome), frequently described in EoE patients.

The overview that our systematic review provides about esophageal perforation in EoE allows us to establish its characteristics and give some clues for risk factors for this complication. To begin with, esophageal perforation appeared in patients of all ages. The predominance of esophageal perforations among the male sex also reflects the unequal distribution of the disease between the sexes, affecting more than twice as many men as women [1]. In addition, esophageal perforation lead to a diagnosis of EoE in two thirds of the patients retrieved in our literature search. In fact, population-based studies defined a peak of incidence of EoE during the third to fourth decades of life [76,77]. This is in agreement with our systematic review, in which half of the patients presented with a perforation during their third to fourth decades and one quarter during the following two decades of life.

Most importantly, potential risk factors for esophageal perforation in EoE are suggested in this systematic review. Firstly, our research identified active inflammation in EoE (both by lack of diagnosis, or absence of anti-inflammatory therapy at the moment of suffering from esophageal perforation) as a relevant risk factor for this complication, with 90% of patients being untreated at the point of suffering from perforation. The minority of patients that were under swallowed steroid or PPI therapy were non responders. Therefore, to prevent this severe complication, it should be a must to treat active EoE with effective anti-inflammatory options.

Secondly, the clinical background of most patients included in this systematic review included a long term dysphagia with repeated food impaction episodes [8,19,21,26,27,30,32–35,40,42,43,49,57,58], with food impaction as the symptom leading to hospital admission [8,19,29,31,42,43,45–50,54,59,60,60,62,66,68–70]. In fact, food impaction is the most frequent clinical manifestation that leads to diagnosis of EoE in adult patients [6,78–80], and its incidence has increase over the last 4 decades, according to a recent single-center research [81]. It frequently requires endoscopic dislodging. A retrospective study of 251 Swiss patients with EoE showed that up to 34.7% at some point required extraction of the impacted bolus by flexible or rigid esophageal endoscopy [8].

Thirdly, we identified using the endoscope to push food into the stomach as a potentially risky maneuver for esophageal perforation in EoE [31,60,66,67,70]. Despite a recent retrospective series showing the push technique to be as safe and effective as the pull technique in managing esophageal food bolus impaction in adults [81–84] and children [85], only a minority of patients had EoE. Until we have prospective studies to assess the safety of pushing the food

Table 3
Description of conservative or surgical treatment options for esophageal perforation in a series of 76 episodes reported in 70 patients with eosinophilic esophagitis. Details are provided as described by authors in source documents included in a systematic review. More than one intervention was possible in the same patient.

Conservative treatment (N = 51)	n (%)	Surgical treatment (N = 25)	n (%)
Broad spectrum antibiotics	30 (58.8)	Thoracotomy and primary suture of the perforation	13 (52)
Bowel rest/fasting	21 (41.2)	Esophagectomy with gastroplasty	5 (20)
Proton pump inhibitors	16 (31.4)	Covering the perforation with intercostal muscle flap	2 (8)
Parenteral nutrition	13 (25.5)	Mediastinal drainages	2 (8)
Esophageal metallic stent	12 (23.6)	Laparotomy and esophageal suture	1 (4)
Enteral nutrition	6 (11.8)	Mediastinoscopy and perforation closure	1 (4)
Endoscopic clipping	2 (3.9)	Evacuation of empyema	1 (4)
Clear liquid diet	2 (3.9)	Needle decompression	1 (4)
Analgesics	2 (3.9)	Esophageal stoma and feeding jejunostomy	1 (4)
Antimicotic agents	1 (1.9)	Section of esophageal septum	1 (4)
Anti-inflammatory agents	1 (1.9)	Decortication of a lung	1 (4)
Unspecified treatment	15 (29.4)	Fistulostomy	1 (4)

bolus into the stomach in patients with known or suspected EoE, caution should be recommended with this technique.

Fourthly, endoscopic procedures in patients with active EoE were also associated with esophageal perforation in our series, with esophageal dilation being the most risky procedure described [32,33,35,43,56,67]. Esophageal strictures are one of the most severe complications of EoE that develop as a result of a long-standing untreated eosinophilic inflammation, with patient age and delayed diagnosis being recognized as its determining factors [12–14]. Fibrostenotic features in EoE should be solved by endoscopic dilation, and dysphagia improves in 95% of patients following dilation [16]. Perforation rates after esophageal dilation in EoE reported in recent studies contrast with those reported in earlier case series; today dilation can be considered safe in EoE when properly performed [86] with a rate of major complications consistent with that reported in other esophageal diseases [16]. Since a high density of eosinophils has been identified as a predictive factor for complications during dilation [87], dilation should be performed after histologic remission has been achieved with an effective diet or implementation of drug-based anti-inflammatory therapy, whenever possible.

Despite the potential severity of an esophageal perforation and its complications, two thirds of the EoE patients described in the literature were effectively treated conservatively, and none of them underwent surgery after failure of the primary treatment. Together with bowel rest and broad-spectrum antibiotics, esophageal stenting to cover the perforation has been revealed in recent years as an effective method that allows oral feeding to continue and promotes accelerate hospital discharge. Surgical repair of the perforation was, by contrast, more common in patients with complications of perforation, in the form of pleural effusion or contrast leakage into the mediastinum. In two cases, a covered stent was required to seal a persistent perforation after surgery [35,37]. Importantly, no death was reported, and the majority of patients could be discharged with the first week after perforation. The young average age of patients with EoE and the fact that it is not associated with serious or debilitating diseases, certainly contributes to these positive results.

Our review has several strengths, such as: compiling results from an exhaustive literature search of three major databases with no time limit on publication date; critically appraising the studies recovered according to their methodology and risk of bias; and different investigators independently extracting the data from the studies included.

However, some limitations should also be acknowledged, including the potential existence of publication bias caused by the limitations commonly imposed by journals to accept individual case reports. Most of the information we retrieved came from single case reports. The possibility of not recovering all the relevant information published on esophageal perforation in EoE was minimized by an extensive literature search that also included abstracts of major gastroenterology congresses. However, a potential underreporting of patients who suffered perforation and had poor results after treatment represents an additional limitation that could bias our results. The impossibility of combining our results in a meta-analysis was a final limitation and also prevented exploring possible publication bias through a funnel plot.

Due to the relatively recent recognition of EoE and its sharp increase in the last two decades, especially in developed countries [1], and the long series of cases identified in this systematic review, we can conclude that esophageal perforation in the context of EoE should not be considered such a rare complication. Preventing perforation in EoE requires improved identification and early diagnosis of patients with suggestive symptoms, treating them with effective medication or diets to suppress eosinophilic inflammation, and to perform careful endoscopic procedures in case of active inflammation. If an esophageal perforation occurs, conservative management, following early identification, should always be the preferred treatment method.

Conflict of interest
None declared.

Appendix A. Supplementary data

Supplementary material related to this article can be found, in the online version, at doi:https://doi.org/10.1016/j.dld.2019.10.019.

References

[1] Navarro P, Arias Á, Arias-González L, et al. Systematic review with meta-analysis: the growing incidence and prevalence of eosinophilic oesophagitis in children and adults in population-based studies. Aliment Pharmacol Ther 2019;49:1116–25.
[2] Lucendo AJ, Molina-Infante J, Arias A, et al. Guidelines on eosinophilic esophagitis: evidence-based statements and recommendations for diagnosis and management in children and adults. United Eur Gastroenterol J 2017;5:335–58.
[3] Lucendo AJ, Arias A, Molina-Infante J. Efficacy of proton pump inhibitor drugs for inducing clinical and histologic remission in patients with symptomatic esophageal eosinophilia: a systematic review and meta-analysis. Clin Gastroenterol Hepatol 2016;14:13–22.
[4] Arias A, Gonzalez-Cervera J, Tenias JM, et al. Efficacy of dietary interventions for inducing histologic remission in patients with eosinophilic esophagitis: a systematic review and meta-analysis. Gastroenterology 2014;146:1639–48.
[5] Murali AR, Gupta A, Attar BM, et al. Topical steroids in eosinophilic esophagitis: systematic review and meta-analysis of placebo-controlled randomized clinical trials. J Gastroenterol Hepatol 2016;31(June):1111–9.
[6] Lucendo AJ, Pascual-Turrion JM, Navarro M, et al. Endoscopic, bioptic, and manometric findings in eosinophilic esophagitis before and after steroid therapy: a case series. Endoscopy 2007;39:765–71.
[7] Hiremath GS, Hameed F, Pacheco A, et al. Esophageal food impaction and eosinophilic esophagitis: a retrospective study, systematic review, and meta-analysis. Dig Dis Sci 2015;60:3181–93.

[8] Straumann A, Bussmann C, Zuber M, et al. Eosinophilic esophagitis: analysis of food impaction and perforation in 251 adolescent and adult patients. Clin Gastroenterol Hepatol 2008;6:598–600.
[9] Lucendo AJ, Arias A, Molina-Infante J, et al. The role of endoscopy in eosinophilic esophagitis: from diagnosis to therapy. Expert Rev Gastroenterol Hepatol 2017;11:1135–49.
[10] Hiremath G, Vaezi MF, Gupta SK, et al. Management of esophageal food impaction varies among gastroenterologists and affects identification of eosinophilic esophagitis. Dig Dis Sci 2018;63:1428–37.
[11] Jacobs JW, Spechler SJ. A systematic review of the risk of perforation during esophageal dilation for patients with eosinophilic esophagitis. Dig Dis Sci 2010;55:1512–5.
[12] Lipka S, Kumar A, Richter JE. Impact of diagnostic delay and other risk factors on eosinophilic esophagitis phenotype and esophageal diameter. J Clin Gastroenterol 2016;50:134–40.
[13] Schoepfer AM, Safroneeva E, Bussmann C, et al. Delay in diagnosis of eosinophilic esophagitis increases risk for stricture formation in a time-dependent manner. Gastroenterology 2013;145:1230–6.
[14] Dellon ES, Kim HP, Sperry SLW, et al. A phenotypic analysis shows that eosinophilic esophagitis is a progressive fibrostenotic disease. Gastrointest Endosc 2014;79:577–85.
[15] Singla MB, Chehade M, Brizuela D, et al. Early comparison of inflammatory vs. fibrostenotic phenotype in eosinophilic esophagitis in a multicenter longitudinal study. Clin Transl Gastroenterol 2015;6:e132.
[16] Moawad FJ, Molina-Infante J, Lucendo AJ, et al. Systematic review with meta-analysis: endoscopic dilation is highly effective and safe in children and adults with eosinophilic oesophagitis. Aliment Pharmacol Ther 2017;46:96–105.
[17] Runge TM, Eluri S, Cotton CC, et al. Causes and outcomes of esophageal perforation in eosinophilic esophagitis. J Clin Gastroenterol 2017;51:805–13.
[18] Ally MR, Dias J, Veerappan GR, et al. Safety of dilation in adults with eosinophilic esophagitis. Dis Esophagus 2013;26:241–5.
[19] Lucendo AJ, Friginal-Ruiz AB, Rodriguez B. Boerhaave's syndrome as the primary manifestation of adult eosinophilic esophagitis. Two case reports and a review of the literature. Dis Esophagus 2011;24:E11–5.
[20] Vernon N, Mohananey D, Ghetmiri E, et al. Esophageal rupture as a primary manifestation in eosinophilic esophagitis. Case Rep Med 2014;2014:673189.
[21] Gunasekaran TS, Berman J, Lim-Dunham JE. Esophageal perforation: an uncommon initial manifestation of eosinophilic esophagitis. Int J Pediatr Adolesc Med 2016;3:123–7.
[22] Moher D, Liberati A, Tetzlaff J, et al. Preferred reporting items for systematic reviews and meta-analyses: the PRISMA statement. BMJ 2009;339:b2535.
[23] Stroup DF, Berlin JA, Morton SC, et al. Meta-analysis of observational studies in epidemiology: a proposal for reporting. Meta-analysis of Observational Studies in Epidemiology (MOOSE) group. JAMA 2000;283:2008–12.
[24] Munn Z, Aromataris E, Tufanaru C, et al. The development of software to support multiple systematic review types: the Joanna Briggs Institute System for the Unified Management, Assessment and Review of Information (JBI SUMARI). Int J Evid Based Healthc 2019;17:36–43.
[25] Cohen MS, Kaufman A, DiMarino AJ, et al. Eosinophilic esophagitis presenting as spontaneous esophageal rupture (Boerhaave's syndrome). Clin Gastroenterol Hepatol 2007;5(2):A24.
[26] Cunneen H, Miller M, Malkaniet A. Spontaneous esophageal perforation due to eosinophilic esophagitis in a teenager. Am J Gastroenterol 2017;112:S1298.
[27] Ehrlich A, Guy S, Smith M. Recurrent esophageal perforation as a presentation of eosinophilic esophagitis. Am J Gastroenterol 2012;107:S248.
[28] El Hajj II, Luz LP, Fayad NF. Intramural esophageal dissection after transesophageal echocardiogram. Dig Liver Dis 2012;44:883.
[29] Giles H, Smith L, Tolosa D, et al. Eosinophilic esophagitis: a rare cause of esophageal rupture in children. Am Surg 2008;74:750–2.
[30] Jackson WE, Mehendiratta V, Palazzo J, et al. Boerhaave's syndrome as an initial presentation of eosinophilic esophagitis: a case series. Ann Gastroenterol 2013;26:166–9.
[31] Jacobs JW, Fatima H, Cote GA, et al. Stenting of esophageal perforation in the setting of eosinophilic esophagitis. Dig Dis Sci 2015;60:1098–100.
[32] Jung KW, Gundersen N, Kopacova J, et al. Occurrence of and risk factors for complications after endoscopic dilation in eosinophilic esophagitis. Gastrointest Endosc 2011;73:15–21.
[33] Krishna SG, Kakati BR, Olden KW, et al. Treatment of eosinophilic esophagitis: is oral viscous budesonide superior to swallowed fluticasone spray? Gastroenterol Hepatol 2011;7:55–9.
[34] Kaplan M, Mutlu EA, Jakate S, et al. Endoscopy in eosinophilic esophagitis: "feline" esophagus and perforation risk. Clin Gastroenterol Hepatol 2003;1:433–7.
[35] Kochar T, Farhan M, McJunkin B. Eosinophilic esophagitis presenting with spontaneous esophageal rupture. JGIM 2018;33:S511–2.
[36] Ngamruengphong S, Kim HJ, Das A, et al. Stepwise circumferential and focal RF ablation using the HALO system in Barrett esophagus (BE) with or without dysplasia: a single center experience. Gastrointest Endosc 2010;71. AB177.
[37] Prabakaran S, Brady P. Spontaneous esophageal perforation due to eosinophilic esophagitis. Am J Gastroenterol 2017;112:S922–3.
[38] Predina JD, Anolik RB, Judy B, et al. Intramural esophageal dissection in a young man with eosinophilic esophagitis. Ann Thorac Cardiovasc Surg 2012;18:31–5.
[39] Rao BB, Thota PN. An uncommon initial manifestation of eosinophilic esophagitis: spontaneous esophageal tear. Am J Gastroenterol 2017;112:S938–40.
[40] Stephens NA, Shah SK, Walker PA, et al. Recurrent spontaneous esophageal dissection. JSLS 2014;18:342–5.
[41] Tariq T, Rizvi A, Badwal K, et al. Spontaneous intramural esophageal rupture: an uncommon presentation of eosinophilic esophagitis requiring endoscopic clipping. ACG Case Rep J 2018;5:e66.
[42] Wallace D, Morrissey S. Threatened esophageal rupture complicating eosinophilic esophagitis. Am J Gastroenterol 2013;108. S-202.
[43] Runge TM, Eluri S, Cotton CC, et al. Causes and outcomes of esophageal perforation in eosinophilic esophagitis. J Clin Gastroenterol 2017;51:805–13.
[44] Cerezo Ruiz A, Parras Mejías E, Martos Becerra JM. A complication following a biopsy sample in eosinophilic esophagitis. Rev Esp Enferm Dig 2017;109:537.
[45] Benítez Cantero JM, Angel Rey JM, Rodríguez Perálvarez M, et al. Esophageal perforation following a biopsy in a patient with eosinophilic esophagitis. Gastroenterol Hepatol 2011;34:460–3.
[46] Fontillon M, Lucendo AJ. Transmural eosinophilic infiltration and fibrosis in a patient with non-traumatic Boerhaave's syndrome due to eosinophilic esophagitis. Am J Gastroenterol 2012;107:1762.
[47] Gómez Senent S, Adán Merino L, Froilán Torres C, et al. Spontaneous esophageal rupture as onset of eosinophilic esophagitis. Gastroenterol Hepatol 2008;31:50–1.
[48] Ibáñez-Sanz G, Rodríguez-Alonso L, Romero NM. Spontaneous intramural esophageal dissection: an unusual onset of eosinophilic esophagitis. Rev Esp Enferm Dig 2016;108:156–7.
[49] Nantes O, Jiménez FJ, Zozaya JM, et al. Increased risk of esophageal perforation in eosinophilic esophagitis. Endoscopy 2009;41:E177–8.
[50] Quiroga J, Prim JMG, Moldes M, et al. Spontaneous circumferential esophageal dissection in a young man with eosinophilic esophagitis. Interact Cardiovasc Thorac Surg 2009;9:1040–2.
[51] Sawatzki M, Schoepfer A, Borovicka J, et al. Stenting after severe iatrogenic submucosal dissection in a patient with newly diagnosed eosinophilic esophagitis. Gastrointest Endosc 2015;81:1499–501.
[52] Sawatzki M, Stienen MN, Straumann A, et al. Endoscopic treatment of paraesophageal abcess in eosinophilic esophagitis after chest trauma. Gastrointest Endosc 2012;76:690–2.
[53] Castaninha S, Lopes JC, Lopes AI. Intramural esophageal dissection. A rare occurrence in pediatric eosinophilic esophagitis. Rev Esp Enferm Dig 2018;110:468–9.
[54] xxx.
[55] Portela M, Maximiano C, Pereira A, et al. Spontaneous esophageal perforation in paediatric age. Gastroenterol Endosc 2018. J Pediatr Gastroenterol Nut 2018;66(Suppl. 2):295.
[56] Eisenbach C, Merle U, Schirmacher P, et al. Perforation of the esophagus after dilation treatment for dysphagia in a patient with eosinophilic esophagitis. Endoscopy 2006;38(Suppl. 2):E43–4.
[57] Fischer A, Höppner J, Richter-Schrag H-J. First successful treatment of a circumferential intramural esophageal dissection with perforation in a patient with eosinophilic esophagitis using a partially covered self-expandable metal stent. J Laparoendosc Adv Surg Tech A 2015;25:147–50.
[58] Spahn T, Vieth M, Mueller M. Paracetamol-induced perforation of the esophagus in a patient with eosinophilic esophagitis. Endoscopy 2010;42:E31–2.
[59] van Rhijn B, Curvers W, Bergman J, et al. Esophageal perforation during endoscopic removal of food impaction in eosinophilic esophagitis: stent well spent? Endoscopy 2014;46:E193–4.
[60] Hendriks DM, Kneepkens CMF, Escher JC, et al. Dysfagie op de kinderleeftijd. TIJDSCHR. KINDERGENEESKUNDE 2011;79:67–70.
[61] Sgrò A, Betalli P, Battaglia G, et al. An unusual complication of eosinophilic esophagitis in an adolescent: intramural esophageal dissection. Endoscopy 2012;44:E419–20.
[62] Liguori G, Cortale M, Cimino F, et al. Circumferential mucosal dissection and esophageal perforation in a patient with eosinophilic esophagitis. World J Gastroenterol 2008;14:803–4.
[63] Fianchi F, De Matteis G, Cianci R, et al. Acute intramucosal dissection in eosinophilic esophagitis. Clin J Gastroenterol 2019;12(6):525–9.
[64] Terrington D, Murugan-Sukumar S, Babar Z, et al. An atypical tension pneumothorax. Am J Respir Crit Care Med 2017;195:A3525.
[65] Riou PJ, Nicholson AG, Pastorino U. Esophageal rupture in a patient with idiopathic eosinophilic esophagitis. Ann Thorac Surg 1996;62:1854–6.
[66] Bosanko N, Chan Y, Lewis M. Eosinophilic oesophagitis: an emerging clinical condition. J R Soc Med 2009;102:244–6.
[67] Irino T, Voultsos M, Tsai JA, et al. Esophagectomy for eosinophilic esophagitis: case report and literature review. Eur Surg 2016;48:241–5.
[68] Gretarsdottir HM, Jonasson JG, Björnsson ES. Etiology and management of esophageal food impaction: a population based study. Scand J Gastroenterol 2015;50:513–8.
[69] Robles–Medranda C, Villard F, Bouvier R, et al. Spontaneous esophageal perforation in eosinophilic esophagitis in children. Endoscopy 2008;40:E171.
[70] Shim LS, Grehan M. Gastrointestinal: oesophageal perforation during endoscopy for food impaction in eosinophilic oesophagitis. J Gastroenterol Hepatol 2010;25:428.
[71] Lucendo AJ, De Rezende L. Endoscopic dilation in eosinophilic esophagitis: a treatment strategy associated with a high risk of perforation. Endoscopy 2007;39:376.
[72] Lucendo AJ, Lucendo B. An update on the immunopathogenesis of eosinophilic esophagitis. Expert Rev Gastroenterol Hepatol 2010;4:141–8.
[73] Lucendo AJ, Arias A, De Rezende LC, et al. Subepithelial collagen deposition, profibrogenic cytokine gene expression, and changes after prolonged fluticasone propionate treatment in adult eosinophilic esophagitis: a prospective study. J Allergy Clin Immunol 2011;128:1037–46.

[74] Schoepfer AM, Simko A, Bussmann C, et al. Eosinophilic esophagitis: relationship of subepithelial eosinophilic inflammation with epithelial histology, endoscopy, blood eosinophils, and symptoms. Am J Gastroenterol 2018;113:348–57.
[75] Landres RT, Kuster GG, Strum WB. Eosinophilic esophagitis in a patient with vigorous achalasia. Gastroenterology 1978;74:1298–301.
[76] Lipowska AM, Kavitt RT. Demographic features of eosinophilic esophagitis. Gastrointest Endosc Clin N Am 2018;28:27–33.
[77] Arias Á, Lucendo AJ. Incidence and prevalence of eosinophilic oesophagitis increase continiously in adults and children in Central Spain: a 12-year population-based study. Dig Liver Dis 2019;51:55–62.
[78] Remedios M, Campbell C, Jones DM, et al. Eosinophilic esophagitis in adults: clinical, endoscopic, histologic findings, and response to treatment with fluticasone propionate. Gastrointest Endosc 2006;63:3–12.
[79] Croese J, Fairley SK, Masson JW, et al. Clinical and endoscopic features of eosinophilic esophagitis in adults. Gastrointest Endosc 2003;58:516–22.
[80] Dellon ES, Gibbs WB, Fritchie KJ, et al. Clinical, endoscopic, and histologic findings distinguish eosinophilic esophagitis from gastroesophageal reflux disease. Clin Gastroenterol Hepatol 2009;7:1305–13.
[81] Schupack DA, Lenz CJ, Geno DM, et al. The evolution of treatment and complications of esophageal food impaction. United Eur Gastroenterol J 2019;7:548–56.
[82] Longstreth GF, Longstreth KJ, Yao JF. Esophageal food impaction: epidemiology and therapy. A retrospective, observational study. Gastrointest Endosc 2001;53:193–8.
[83] Vicari JJ, Johanson JF, Frakes JT. Outcomes of acute esophageal food impaction: success of the push technique. Gastrointest Endosc 2001;53:178–81.
[84] Heerasing N, Lee SY, Alexander S, et al. Prevalence of eosinophilic oesophagitis in adults presenting with oesophageal food bolus obstruction. World J Gastrointest Pharmacol Ther 2015;6:244–7.
[85] Kriem J, Rahhal R. Safety and efficacy of the push endoscopic technique in the management of esophageal food bolus impactions in children. J Pediatr Gastroenterol Nutr 2018;66:e1–5.
[86] Sami SS, Haboubi HN, Ang Y, et al. UK guidelines on oesophageal dilatation in clinical practice. Gut 2018;67:1000–23.
[87] Cohen MS, Kaufman AB, Palazzo JP, et al. An audit of endoscopic complications in adult eosinophilic esophagitis. Clin Gastroenterol Hepatol 2007;5:1149–53.